



NEET-PG

PART

VOLUME

Cardiology
Oncology



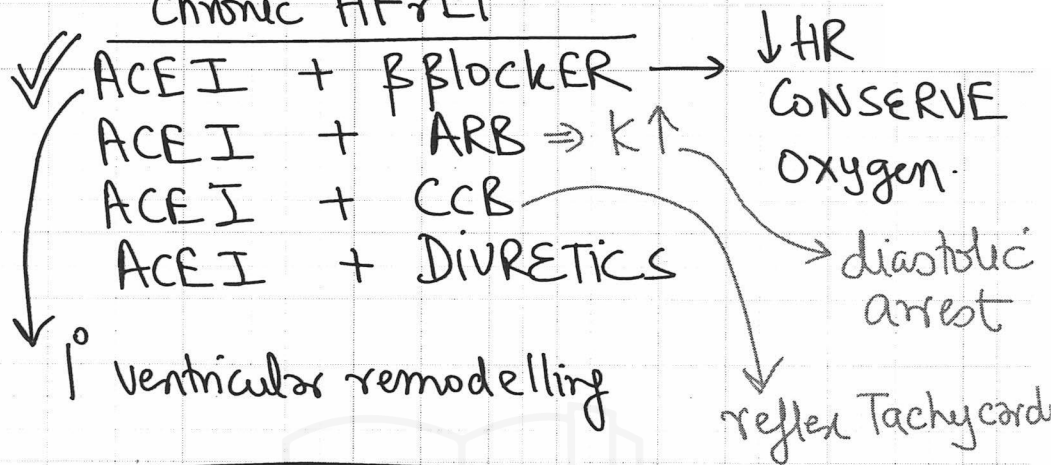
CARDIOLOGY

1. Cardiology	1-42
2. Structural Damage	43-61
3. Pericardial Effusion	62-75
4. Pons	76-86
5. Fungal Meningitis	87-128
6. Hyponatremia	129-149
7. Carcinoid Tumors	150-170
8. Azotemic Osteodystrophy	171-201
9. Imminent Respiratory Failure	202-243
10. Cirrhosis	244-262
11. Whipple Disease	263-284

GENERAL ONCOLOGY

- | | |
|----------------------------|----------------|
| 1. Oncology | 285-320 |
| 2. Invasion | 321-325 |
| 3. Haemato Oncology | 326-345 |

major mortality reduction
chronic HF r EF



HF β EF HF r EF acute HF r EF chronic	ARNI LMNOP + vasopressor support ACEI + β blocker Metoprolol CARVEDILOL * Bisoprolol
---	---

HTN

(N): 115/75 mm Hg

120-139 / 80-89 = PRE HTN

$> \frac{140}{90}$ and/or = HTN = 2 consecutive readings

$\frac{160}{80}$ $\frac{120}{100}$ $\frac{160}{100}$ ✓
 ✓ $\frac{100}{100}$

Isolated diastolic HTN

1. Essential HTN
2. Hypothyroidism
3. Coarctation
4. Cushing

140-159 / 90-99 = stg I

$> 160 / 100$ = stg II

MC Co2 HTN = essential / idiopathic
 MC Co2 HTN = chronic glomerulonephritis > O.S.A.
 pediatrics: MC Co2 HTN = chronic glomerulonephritis

Home BP recording
 $> 135 / 85$ mm Hg

<u>HTive CRISIS emergency</u>	<u>HTive URGENCY</u>
<p>> $\frac{180}{120}$ + Target organ damage</p> <p style="padding-left: 40px;">Papill edema Aortic dissection LVH</p>	<p>> $\frac{180}{120}$</p> <p>Rx: → oral ACEI</p>

Rx: &

* (CNS event)

↳ iv Nicardipine > LABETALOL

Sodium nitroprusside avoided

- iv URADIPIL
- iv FENOLDOPAM
- iv Hydralazine
- iv phentolamine (pheochromocytoma Sx)
- iv LABETALOL
- iv FUROSEMIDE

TARGET BP : MAP ↓ 25% OVER 24-48 HOURS

TARGET ORGAN Damage

<p>✓ HEART ✓ EYES</p>	<p>BRAIN Kidney</p>	<p>AORTA</p>
---------------------------	-------------------------	--------------

↳ LVH: 1st affected

↳ demand ↑ : sub-endocardial ischemia : Chest pain
supply ↓ : angine

HTive Retinopathy &

I → focal ATTENUATION ARTERIOLES

II → I + A-V nipping/nicking (SALU-SIGN)

III → I + II + flame shaped hemorrhage &
Cotton wool spots

IV → I + II + III + Papill edema &

D. Retinopathy ⇒ MICROANEURYSM FORMATION

Kidney #: Benign nephrosclerosis

* GFR ↓ calculation ⇒ CKD-EPI formula
COCKROFT gault formula

Inulin
 PAH Clearance
 UREA
 glucose

* GFR ↓ < $60 \text{ ml/min/1.73m}^2$ × $\frac{3}{\text{months}}$

C.K.D → Tx ⇒ < $30 \text{ ml/min/1.73m}^2$
 dialysis

ESRD = < $15 \text{ ml/min/1.73m}^2$

BRAIN: HEMORRHAGIC STROKE

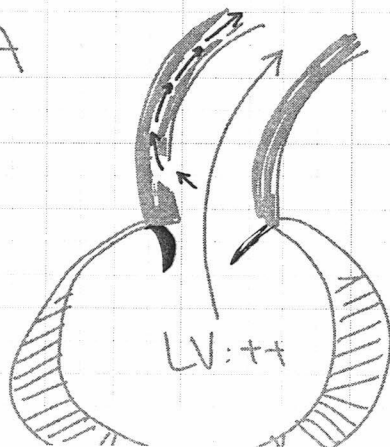
* MC site: PUTAMEN

* IOC: NCCT HEAD

* THROMBOLYSIS CI

* ↑↑ ICP ⇒ VENTRICULOSTOMY

AORTA



AORTIC DISSECTION

HTN: 70% ↑

MARFAN SYN

CYSTIC Medial necrosis

SYPHILIS

Chest pain: DIFFUSE, REST @
 site: interscapular Area

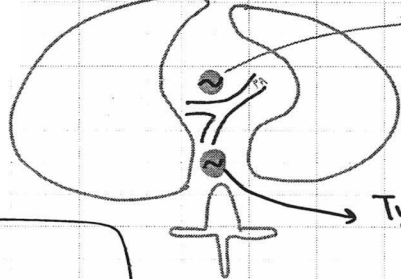
antegrade: ICA: ischemic STROKE

Retrograde: coronary A dissection

Type 1 MI *

Hemodynamically unstable: T.E.E.

stable: MRI chest



Type A: asc. Aorta: Sx Repair

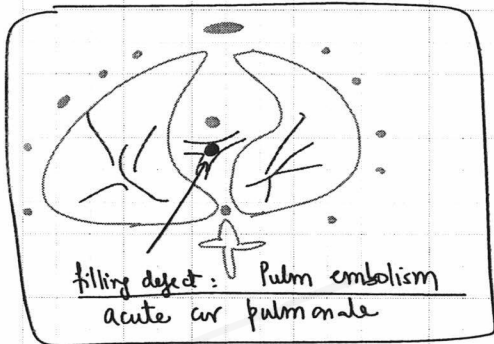
Tennis ball = Aortic dissection (intimal flap)

Type B: desc Aorta
: Esmolol

Type B aortic dissection + HTN CRISIS \Rightarrow iv Labetalol

Hydralazine CI

medical Tx failure \rightarrow Sx Repair



filling defect: Pulm embolism acute cor pulmonale

Hematological = undiagnosed HTN

= M.A.H.A microangiopathic hemolytic anemia

[HUS, T.T.P, metallic valve, HTN]

Rx: DASH: dietary approach To stop HTN⁴⁶

HTN

DRUGS:

< 55yr \rightarrow ACEI or ARB

\geq 55yr \rightarrow CCB

30yr: HTN: ACEI + CCB + DIURETICS
Ramipril amlodipine THIAZIDE

60yr HTN: CCB + ACEI + DIURETICS

RESISTANT HTN: \geq 3 Classes anti HTN medics (must include: THIAZIDE)

MC 1. non compliance

2. R.A.S: MRA

3. CoNN: Salt loading test

4. pheochromocytome \Rightarrow plasma metanephrine levels.

UNCONTROLLED BP

\rightarrow low dose dexamethasone supp
5. Cushing syndrome

24 hr U. Vanijl Mandelic acid
 ↓
NEURDBLASTOMA

pheochromocytome
 screening ⇒ 24 hr U. fractionated metanephr
 IOC ⇒ plasma " "
 DOC HTN ⇒ ORAL phenoxybenzamine
 Intra HTN CRISIS ⇒ IV phentolamine
 Op pho Sx

- * HTN + chronic stable angina = Metoprolol
- * HTN + chronic CCF ⇒ Metoprolol

RAS U/L ⇒ ACE ⊖
 RAS B/L ⇒ ACE ⊖ CI
 ↳ P.T.R.A + stenting
 Percutaneous Trans-luminal
 Renal angioplasty stenting
 MC w/ RAS ⇒ ATHEROSCLEROSIS
 MC w/ RAS (India) ⇒ Takayasu A
 MC w/ RAS: 20yr ♀ ⇒ Fibromuscular dysplasia
 IOC w/ RAS: M.R.A
 Doppler
 digital
 subtraction
 angiography

Contrast induced nephropathy
 ↓
 N-acetyl cysteine

chronic stable angina: $\geq 70\%$ blockage in any
 diffuse Chest pain Coronary A

Recurrent presentation

50yr: HTN: Senior Manager
 walking fast Towards CAR
 Chest pain on EXERTION/EMOTION: LEVINE \oplus
 Relief on REST
 duration < 10 minutes
 POST-PRANDIAL ANGINA

↑
 LEVINE \oplus
 SIGN

ECG = NORMAL
 (asymptomatic)

ECG \Rightarrow ST \downarrow
 (symptomatic) S.L. NTG
 Repeat ecg \Rightarrow ST \odot

REVERSIBLE
ischemie

STRESS TESTS

Treadmill TEST: \uparrow speed \uparrow incline @ 3min
 TARGET HR = 85% (220 - Age)
 ECG \Rightarrow ST $\downarrow \geq 1\text{mm} \geq 80$ msec: 2 leads
 STOP THE TEST contiguous

TMT: CI: PARAPLEGIA
 NEUROPATHIC ULCER
 CHARCOT JOINTS
 BUERGER'S
 OA BIL knee

morbid obesity
 severe aortic stenosis: absolute CI

unstable angina
 MI < 48 hours

BRUCE PROTOCOL
 sensitivity = 80%

\otimes morbid obesity, chronic stable angina

STRESS Echocardiography

IV dobutamine: $\beta_1 \oplus$: HR \uparrow : $\uparrow O_2$ consumption

\checkmark ECG \Rightarrow ST $\downarrow \geq 1\text{mm} \geq 80$ msec: 2 contiguous lead

\checkmark Echo \Rightarrow Regional hypokinesia

SENSITIVITY $\Rightarrow 90\%$

NUCLEAR SCANS
MYOCARDIAL PERFUSION IMAGING

Thallium - 201 : gamma CAMERA = Thallium SCAN
 Tc 99 : " = SESTAMIBI SCAN

SENSITIVITY = 95%

* MYOCARDIAL VIABILITY = Revascularization benefit procedure
 P.E.T SCAN

- * mv: C.S.A
1. IMT : 80%
 2. STRESS Echo : 90%
 3. SESTAMIBI : 95%

gold sta ⇒ 4. Coronary angiography : Real Time evidence
 Radial A, femoral A approach

- ✓ no of blockages
- ✓ Site of blockage
- ✓ % of blockage

DOC CSA / HIBERNATING MYOCARDIUM
 REVERSIBLE ischaemia



β-blocker : METOPROLOL

major mortality ↓ drug in CSA = Metoprolol

Rx C.S.A

1. Tab. Aspirin 75mg OD (mortality ↓)
 or Clopidogrel 75mg OD

2. S.L. NTG = emergency USE ←
 Buccal spray NTG ↑
 Trans-dermal patch NTG

no mortality benefit

3. Tab. isorbide mononitrate : post prandial angina
4. Tab. METOPROLOL
 ↓ HR : CONSERVE fuel (mortality ↓)
5. Tab. ATORVASTATIN 80mg

6. B6/g/12 : Homocystinemia

7. STOP SMOKING

Nicotine deaddiction ⇒ Nicotine buccal spray
VARENICLINE
 MOA: $\alpha_4 \beta_2$ nicotine Receptor : partial agonist

8. alcohol deaddiction ⇒ acamprosate + Naltrexone
 BUPROPION, CLONIDINE Trans-dermal PATCH
 ↓
 sedation

FAILURE OF Medical Therapy

9. RANOLAZINE ✓
 IVABRADINE
 TRIMETAZIDINE

CORONARY ANGIOGRAPHY

Triple vessel D : LAD LCX RCA
 ↓ ↓ ↓
 ant lateral inferior
 → (C.T.V.S) ⇒ C.A.B.G

CABG	PATENCY Rate
1. int Mammory A	15-20 yrs
2. great saphneous vein	10-12 yrs
3. Radial ARTERY	5yr
4. gastroepiploic A	5yr

Single vessel D

Ticlopidine
 PRASUGEL

PRE-OP before procedure ⇒ oral TICAGRELOR *
 ⇒ inj enoxaparin sc *

during procedure ⇒ iv abciximab
 a iv eptifibatide *
 iv Tirofiban

Baloon dilatation
 debris → platelet plug → clot → MI : Type 4A MI
 during P.C.I ↑ Troponin X 5 Times

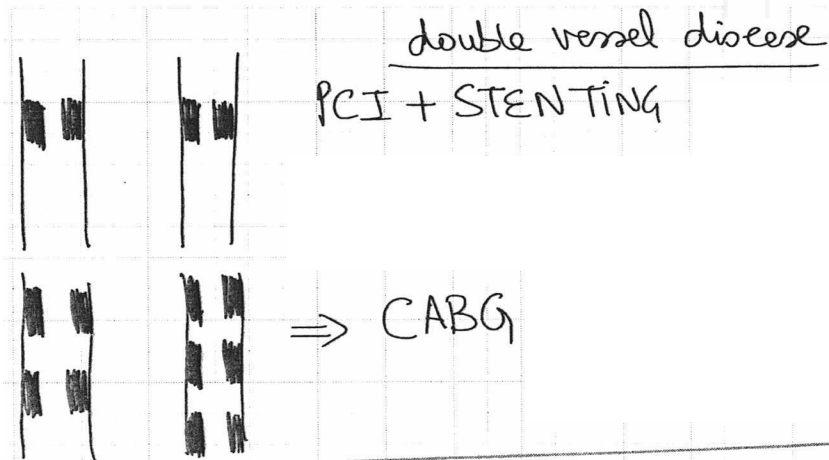
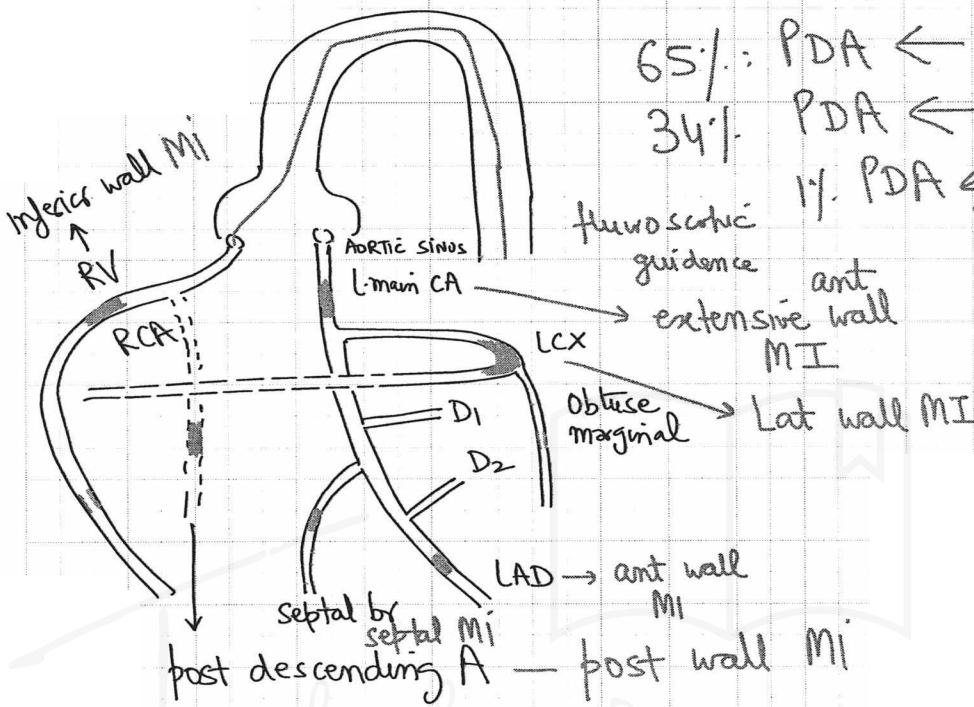
→ PCI + STENTING : drug eluting ⇒ EVEROLIMUS
 SIROLIMUS

BARE Metal stents : Type 4B MI

LATENT stent
 THROMBOSIS

Coronary dominance: PDA

65%: PDA ← RCA: Rt domū
 34%: PDA ← LCX
 1%: PDA ← RCA Co-dor
 ← LCX



- CABG

 1. Triple vessel D
 2. double " D ⊆ multisites #
 - * 3. LAD Blockage ⊆ EF% < 40%

Stunned myocardium
 ↓
 MI

CSA / HIBERNATING myocardium
REVERSIBLE ischemic

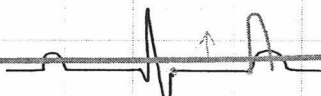
- ✓ Troponin I = NORMAL
- ✓ Ist = T.M.T
- ✓ deconditioning in a patient = STRESS echo
- ✓ ACCURACY: SESTAMIPI
 ⇒ STRESS echo
- ✓ Myocardial viability = PET SCAN
- ✓ Coronary angiography = decision making


REVASCU LARIZATION STRATEGY

←
 PCI + STENT
 S.V.D / D.V.D

→
 CABG

Myocardial infarction **CURRENT of injury MI**
 = ST ↑

ECG ⇒ 

1. HYPERACUTE T wave : seconds:	ISCHEMIA
2.  PARDEE TOMB STONE	↓ INJURY ↓
3. deep Q wave : > 1 hr : cell death PERSISTS FOR whole life OLD / PREVIOUS MI q = septal ⊕ ⇒ < 40 msec < 1 mm ↳ V ₅ , V ₆	DEATH

- LEVINE SIGN: > 20 min
1. ECG → STEMI vs NSTEMI
 → SURFACE involved
 → Time elapsed
- and/or
2. Troponin I normal < 0.04 mg/L
- ↓
 RISE > 3 hr
 Serial Trop I: admission
 3 hr
- × 2 × 3 × 5 × 10
 ↓ ↓
 Type 4A Type 5
 MI MI
- ME coz S.C.D in ⇒ V. fibrillation
 MI
 Poor at localizing: LCX⁶¹ &
 Thrombus

BEST/IOC / most specific TEST MI = Trop I

1st mv: suspected MI = ECG

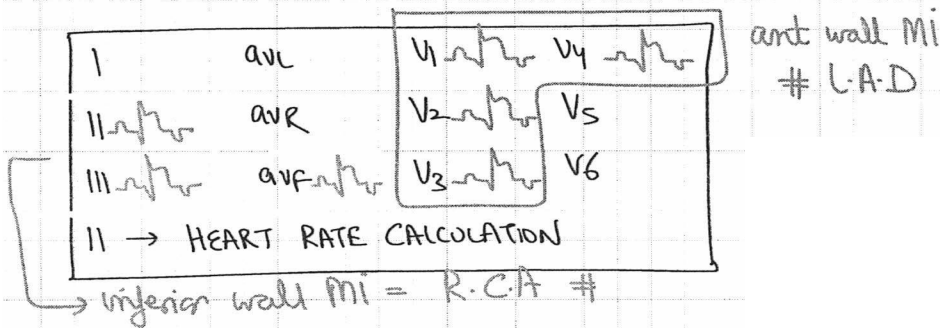
SILENT MI: D. NEUROPATHY

Sudden cardiac death in DM ⇒ SILENT MI

REINFARCTION ⇒ Trop I: ↑ 20% baseline

REINFARCTION > 72 hr ⇒ CPK-MB
Creatine phosphokinase - Myocardial B:

- H.F.A.B.P
HEART fatty-acid binding PROTEIN
- * ✓ 1st To Rise in MI = $\frac{\text{H.F.A.B.P}}{\text{myoglobin}}$
- * LAST TO RISE in MI ⇒ LDH



65yr: HTN, SMOKER

8am: Levine sign ⊕
diaphoresis
dyspnea on exertion

ORTHOPNEA

Pink frothy sputum

11am: O/E: HR = 110/min, BP = 160/100
neck veins full

diaphragm: loud S₁
: narrow split S₂

Bell : S₃ ⊕

lung : BIL FINE CREPES

ECG ⇒ ST ↑ : 3mm : V₁-V₄

Troponin I ⇒ 0.08 ng/L

STEMI ant wall

Rx: 1. M.O.A.N morphine - O₂ - Aspirin - NTG

O₂: ASPIRIN 325mg chewable aspirin

Buccal mucosa : ⊖ TxA₂

Clopidogrel 300mg

SL-NTG 0.4mg, Repeat @ 5min

max = 3 OVER 15min

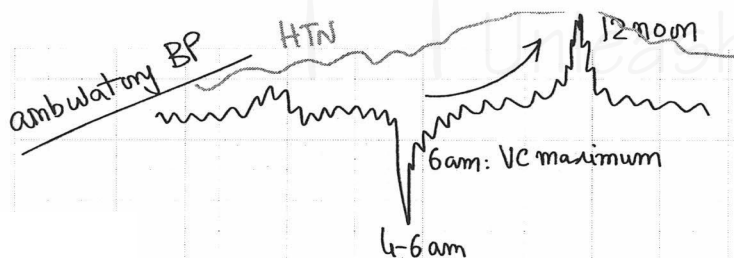
venodilator : CI: SBP < 80 mmHg

3mg iv morphine : ↓ pulm oedema

Vasopressin : ↓ infarct size

↓ AIR-HUNGER

dual antiplatelet therapy



② iv Metoprolol (↓ infarct size)

③ inj enoxaparin s.c

④ pulm edema: iv FURSEMIDE
iv ENALAPRILAT
iv NTG DRIP

⑤ CATH LAB: Femoral A : seldinger technique
Coronary angiography : LAD #
Balloon angioplasty

primary P.C.I : DOOR To device = < 90 min
Time

OR

THROMBOLYSIS : DOOR To needle Time : < 30 min

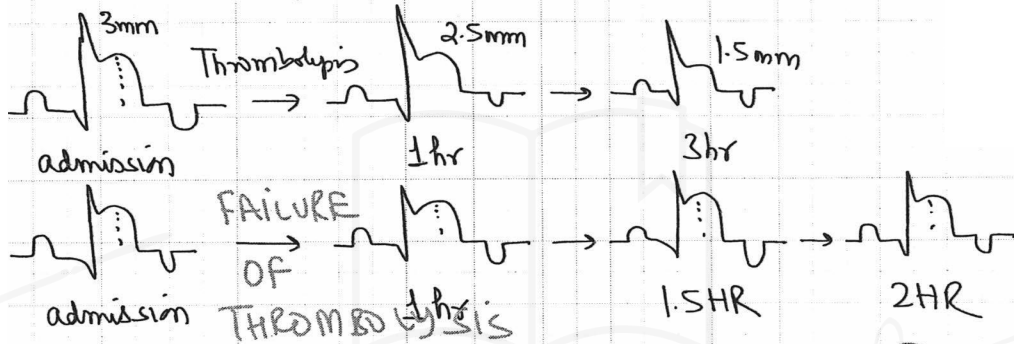
Bleeding
I.C.H
=

{ ALTEPLASE : INFUSION → least incidence of bleeding.
RETEPLASE : BOLUS
TENECTEPLASE : BOLUS
STREPTOKINASE INFUSION 1.5MU, 5/D, 60 min

S.T.K : Streptococcus & EQUISIMILUS

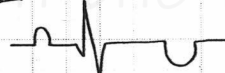
antigenic drug : anaphylaxis Risk
 Re-use > 6mth of previous USE
 anaphylaxis = death = LARYNGEAL edema
 Rx : inj Adrenaline [undiluted] 1:1000
 0.5ml

Intramuscular



Rescue P.C.I : < 90 min @ start of Thrombol

65yr ♂ : LEVINE SKIN
 NARROW split S₂

ECG = V₁-V₄ ⇒ 
 Twave inversion

Trop I = 0.08 ng/L

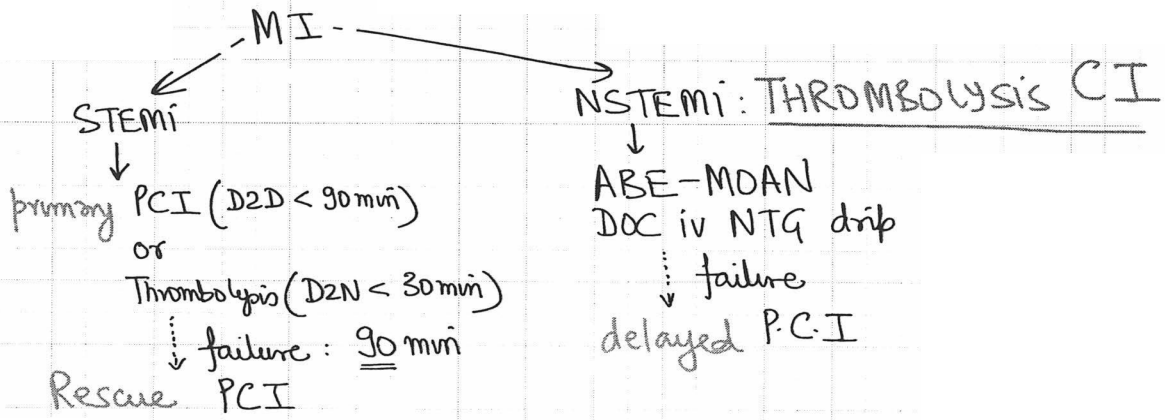
NSTEMI	ant wall
--------	----------

Rx ⇒ ABE - MOAN
 IV abiximab
 IV β blocker: Metoprolol
 inj enoxaparin sc
 morphine - O₂ - Aspirin (NTG)

DOC NSTEMI = iv NTG DRIP

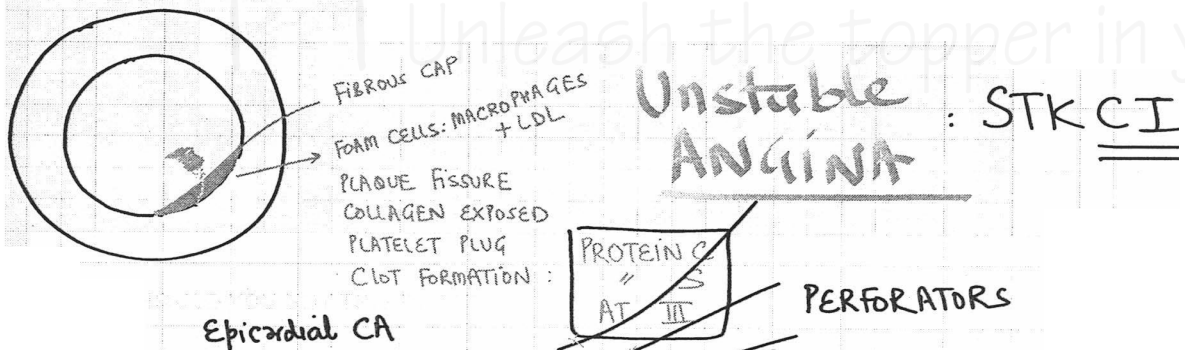
SpO₂ ↓↓ BP ↓↓ CREPTS ++

delayed P.C.I



- PCI
1. chronic stable angina
 2. STEMI = primary, Rescue.
 3. NSTEMI = delayed

✓ 8447982490
 dmtsnavleen@gmail.com



Unstable ANGINA : STK CI

ATHEROEMBOLISM

60yr HTN/SMOKER/MALE

CHEST PAIN REST, DIFFUSE x 3 hrs

ECG ⇒ ST (N) = 50%
 ST ↓ = 25%
 Twave inversion = 25%

TROP I ⇒ 0.06 ng/L [x2 Trop I = MI]